CPR induced inappropriate shocks from a subcutaneous implantable cardioverter defibrillator during out-of-hospital cardiac arrest

CMOREJ Patrik Christian[1,2], PERAN David[3,4], SMRZOVA Eva[1], BULIKOVA Tana[5,6], PEKARA Jaroslav[3,7]

[1] Emergency Medical Services of Usti nad Labem region, Czech Republic, [2] Jan Evangelista Purkyne University, Faculty of Health Studies, Usti nad Labem, Czech Republic
[3] Prague Emergency Medical Services, Prague, Czech Republic, [4] Division of Public Health, 3rd Faculty of Medicine, Charles University in Prague, Czech Republic
[5] Slovak Medical University, Faculty of Nursing and Professional Health Studies, Bratislava, Slovakia, [6] EMS Life Star Emergency, Pre-Hospital EMS LLC, Limbach, Slovakia
[7] Medical College, Prague, Czech Republic

EUSEM PRAGUE 2019 12-16 OCTOBER
THE EUROPEAN EMERGENCY MEDICINE CONGRESS
www.eusem.org
PRAGUE

1. INTRODUCTION

A subcutaneous implantable cardioverter defibrillator (S-ICD) is a device designed for the treatment of ventricular tachycardia or ventricular fibrillation. It represents an alternative to the transvenous implantable cardioverter defibrillator (TV-ICD)[1].
A major advantage of S-ICD is the subcutaneous positioning of the electrodes (Figure 1), which eliminates complications associated with the intravenous implantation of electrodes. In general, there is a lower risk of infectious complications and bleeding[2,3]. The S-ICD is as effective in terminating induced ventricular fibrillation as TV-ICD, although it requires higher energy levels (36.6±19.8 J vs. 11.1±8.5 J, p<0,001)[4].

2. DISCUSION

Inappropriate shocks are most often induced by supraventricular tachycardia and T-wave oversensing. T-wave oversensing develops because of high T-wave amplitude, which the S-ICD interprets as another QRS complex. This leads to double counting. Smart Pass function was off and this led to an increase in the S-ICD's sensitivity and to double counting of wide QRS artefacts.

3. CASE REPORT

We present the case of a 30-year-old man with a subcutaneous implantable cardioverter defibrillator (S-ICD) who suffered sudden out-of-hospital cardiac arrest. Despite rhythm on the EMS monitor showed asystole throughout the period of resuscitation (Figure 2), the patient received inappropriate shocks due to oversensing of chest compressions (Figure 3) and a bystander performing chest compressions received a shock delivered by the S-ICD. This was so unpleasant that the bystander refused to continue with chest compressions.
A magnet – M50 (Biotronic Company) – was placed over the device because of repeated defibrillation shocks from S-ICD had occurred. Despite these measures, further S-ICD shocks were delivered during the resuscitation. Resuscitation was terminated after 30 minutes, once all therapeutic options and all possible reversible causes of cardiac arrest had been exhausted.

4. RECOMMENDATION

I. Visible scars on the chest in a typical location should alert the paramedics to the presence of an S-ICD (Figure 4).

II. The S-ICD manufacturer (Boston Scientific) recommends using the 6860 magnet from Boston Scientific or the 4520 magnet from Cameron Health. To inhibit shock delivery, the magnet must be placed above the upper or lower edge of the S-ICD generator. Successful inhibition of shock delivery by the magnet is signalised acoustically as beeping for 60 seconds. If no acoustic signal is detected following the magnet's placement above the upper or lower edge, then the magnet must be moved vertically and horizontally in the target zone as shown by the arrows (Figure 5).

III. The external electrodes should be placed as far awa as possible from the S-ICD components. The authors of this case report favour the anterior-posterior positioning of external defibrillator electrodes.

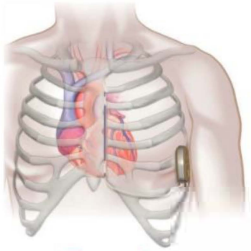

Figure 1

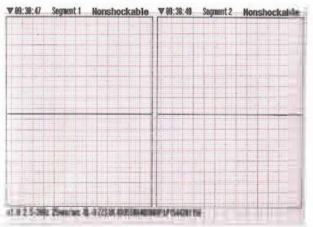

Figure 2



Figure 3

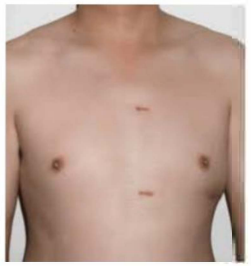

Figure 4

Figure 5

5. CONCLUSION

Out-of-hospital resuscitation of a patient with an implanted S-ICD places greater demands on the knowledge, experience and skills of EMS paramedics and physicians. Inappropriate shocks and the specificities of magnet placement to inhibit shock delivery may decrease the quality of resuscitation.

Presenter:
Patrik Christian Cmorej
Emergeny Medical Services of the Usti nad Labem Region
Socialni pece 799/7a, Usti nad Labem

Email: cmorej.patrik@zzsuk.cz
Web: www.zzsuk.cz

REFERENCES

UNIVERZITA J. E. PURKYNĚ V ÚSTÍ NAD LABEM